

Follicular Conjunctivitis

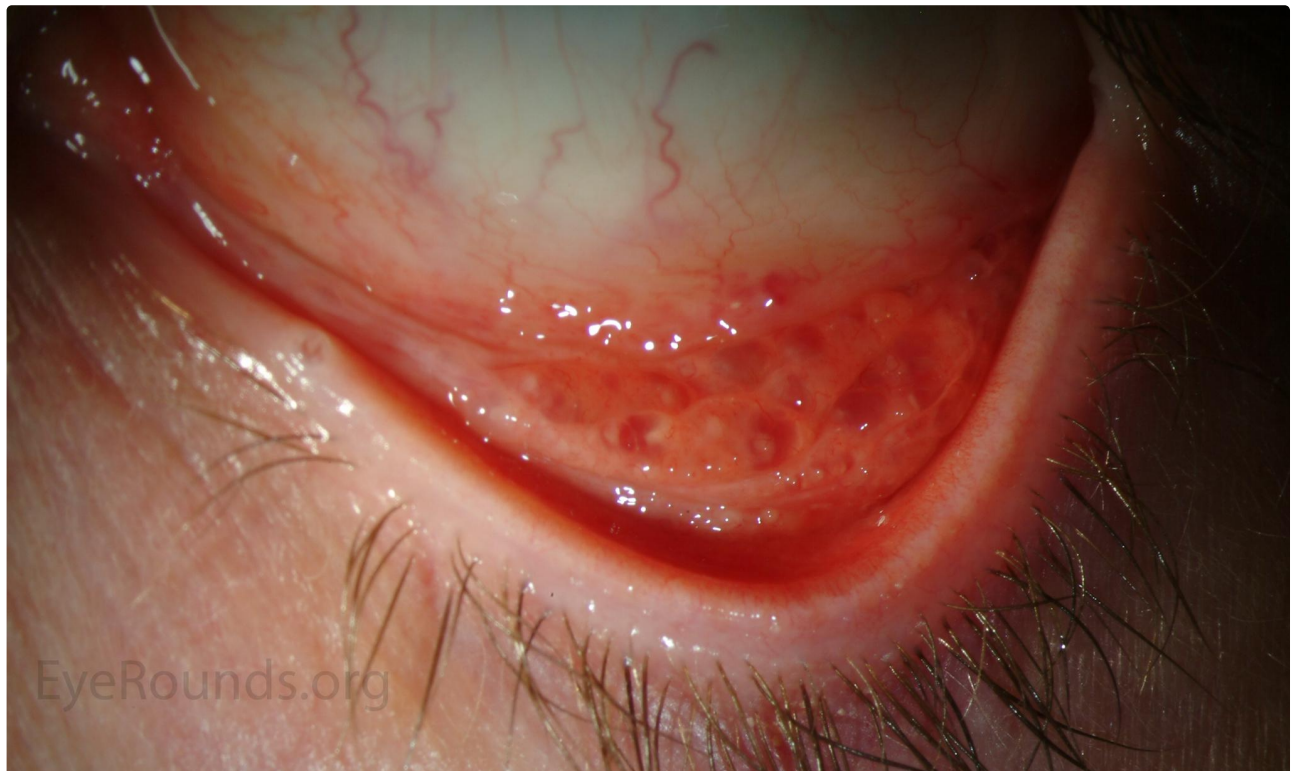
Category(ies): Cornea, External Disease

Contributor: [Jesse Vislisel, MD](#)

Photographers: Ed Heffron (patient 1), Stefani Karakas, CRA (patient 2)



Conjunctival follicles are round collections of lymphocytes, often most prominent in the inferior fornix. Blood vessels may overlie the follicles, but are not a prominent component within them. This helps differentiate follicles from conjunctival papillae. These photographs come from two different patients with different presentations of follicular conjunctivitis.

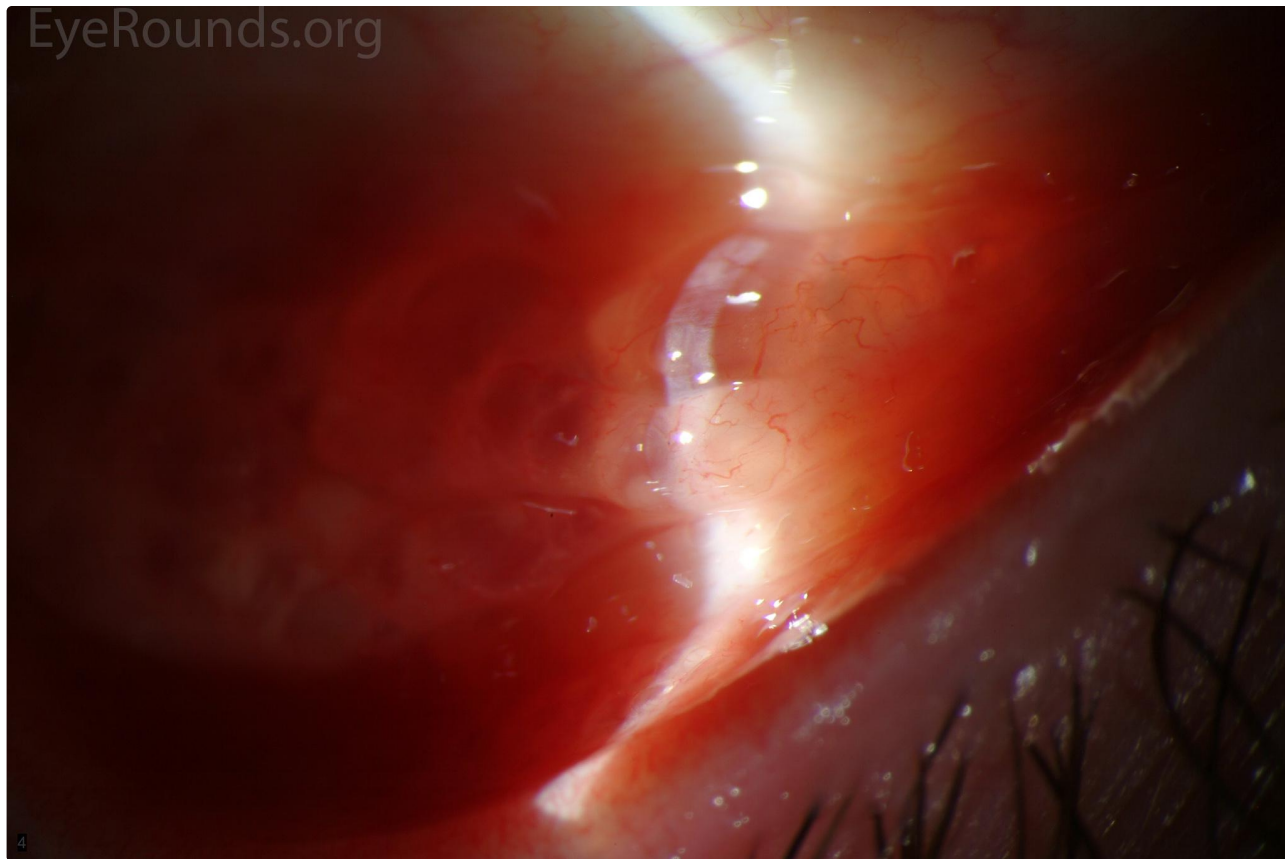


Patient 1

Patient has folliculosis due to viral conjunctivitis.

 [Enlarge](#)

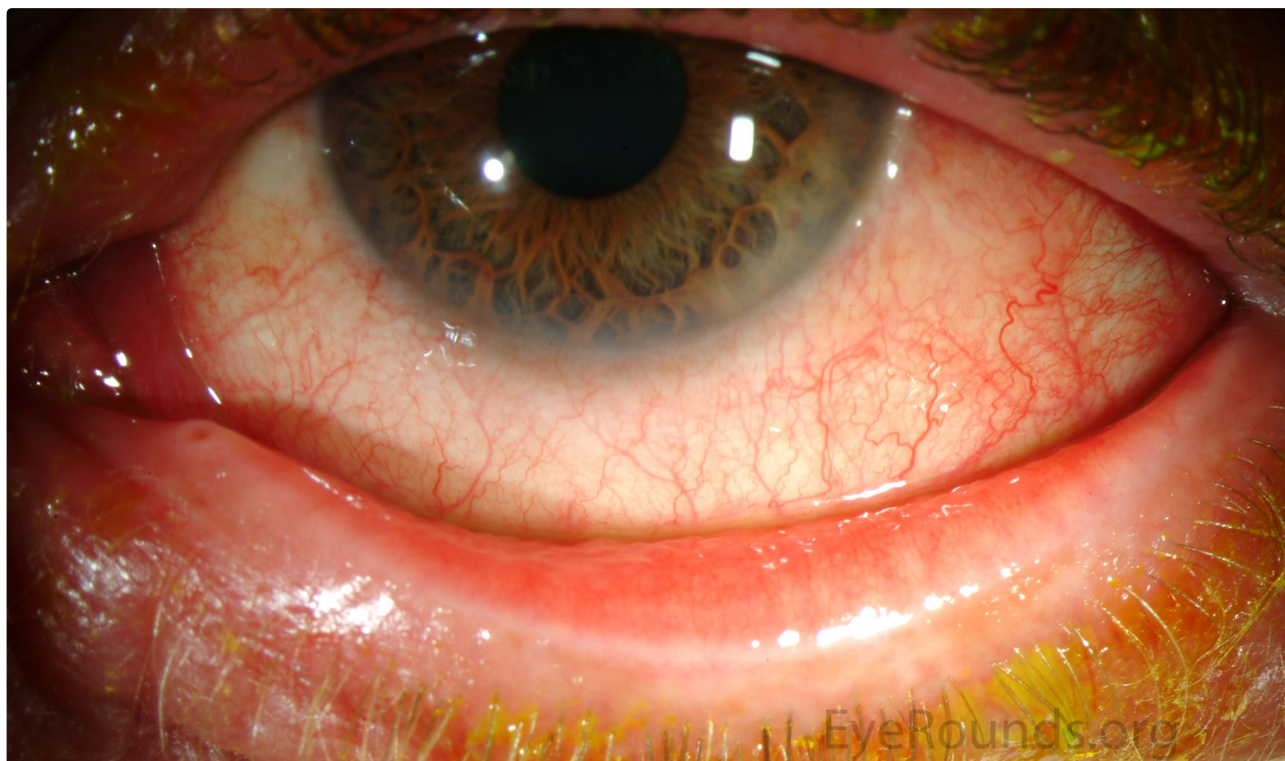 [Download](#)



Patient 1

[Enlarge](#)

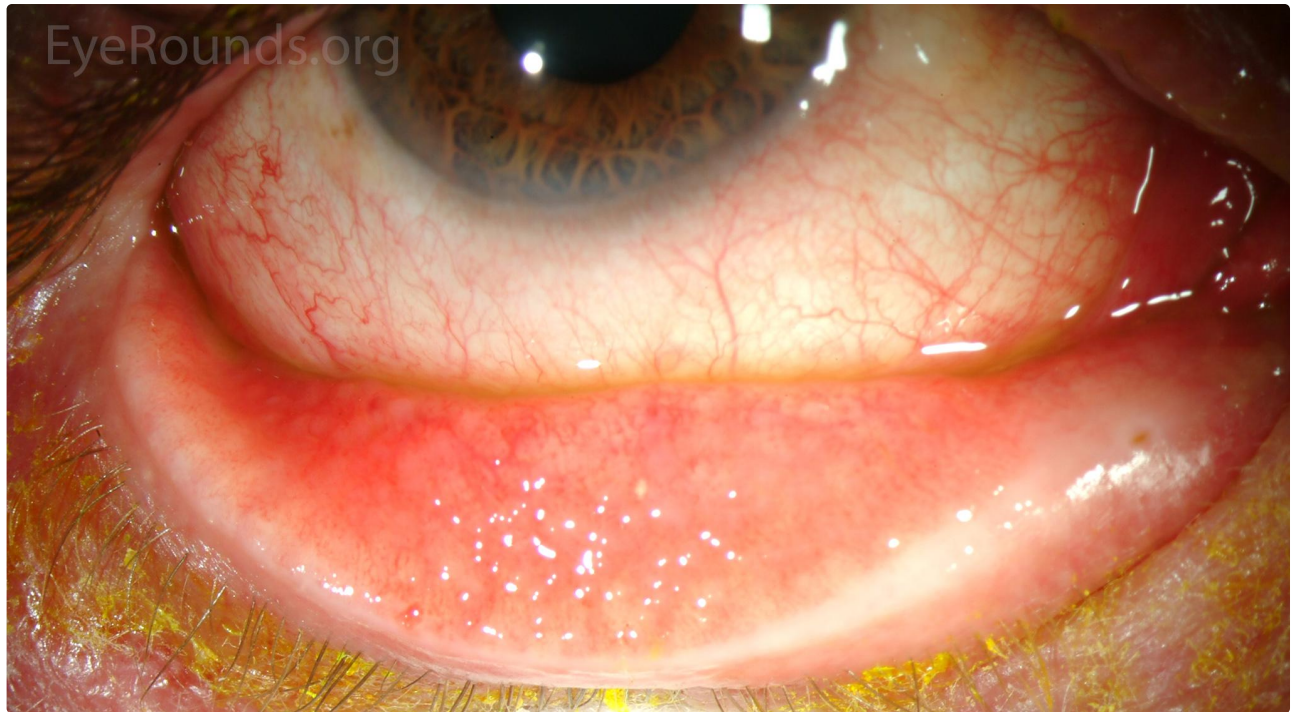[Download](#)



Patient 2
Patient has follicular reaction resulting from allergy to brimonidine drops.

 Enlarge

 Download



Patient 2

 Enlarge

 Download

Image Permissions:



Ophthalmic Atlas Images by [EyeRounds.org](https://www.eyerounds.org), [The University of Iowa](https://www.theuniversityofiowa.edu) are licensed under a [Creative Commons Attribution-NonCommercial-NoDerivs 3.0 Unported License](https://creativecommons.org/licenses/by-nc-nd/3.0/).

Address

University of Iowa
Roy J. and Lucille A. Carver College
of Medicine
Department of Ophthalmology and
Visual Sciences
200 Hawkins Drive
Iowa City, IA 52242

[Support Us](#)

Legal

Copyright © 2019 The University of
Iowa. All Rights Reserved
[Report an issue with this page](#)
[Web Privacy Policy](#) |
[Nondiscrimination Statement](#)

Related Links

[Cataract Surgery for Greenhorns](#)
[EyeTransillumination](#)
[Gonioscopy.org](https://gonioscopy.org)
[Iowa Glaucoma Curriculum](#)
[Iowa Wet Lab](#)
[Patient Information](#)
[Stone Rounds](#)
[The Best Hits Bookshelf](#)

EyeRounds Social Media

Follow



Receive notification of new cases,
[sign up here](#)
[Contact Us](#)
[Submit a Suggestion](#)